

Effect of Garlic Extract on Liver Histopathology of BALB/c Mice with Nicotine Exposure

Widya Mutiara Karoline¹⁾, Desy Armalina²⁾, Neni Susilaningsih²⁾, Hermawan Istiadi³⁾, Akhmad Ismail^{2)*}

¹Undergraduate Student, Faculty of Medicine, Diponegoro University, Semarang

²Department of Anatomy and Histology, Faculty of Medicine, Diponegoro University, Semarang

³Department of Anatomical Pathology, Faculty of Medicine, Diponegoro University, Semarang

* Email : akhmadismaildr@yahoo.com

Diterima 6 Juli 2022

Disetujui 24 September 2022

Dipublikasikan 24 Oktober 2022

Abstract

Nicotine affects liver in the presence of free radicals. One of the antioxidants is allicin which is the most abundant organosulfur in garlic. The objective of this study is to determine the effect of garlic extract as an antioxidant on the liver histopathological features of BALB/c mice exposed to nicotine. This is an experimental study with with post-test only control group design. The research subject were 24 male BALB/c mice. The K- group was the healthy control. The K+ group was exposed to inhaled nicotine of 10 mg/kgBW. Groups P1 and P2 were exposed to 10 mg/kgBW inhaled nicotine and were given garlic extract 300 mg/kgBW and 500 mg/kgBW. Treatment was given for 14 days. Data were analyzed by Kruskal-Wallis test and considered significant if the p value <0.05 with 95% confidence interval. Liver degeneration was grouped into normal, parenchymatous degeneration, hydropic degeneration, and necrosis. The results in the following groups: K: 80%, 20%, 0%, 0%; K(-): 0%,0%,87%,13%; P1 : 0%,60%,40%,0%; P2 : 0%,100%,0%,0%. There was a significant difference in the degree of degeneration between groups ($p < 0.001$). Garlic extract can reduce the degree of microscopic damage to the liver of BALB/c mice exposed to nicotine inhalation.

Key words: garlic, liver, nicotine, histopathology

Abstrak

Nikotin mempengaruhi hati dengan adanya radikal bebas. Allicin adalah salah satu antioksidan yang merupakan organosulfur yang paling banyak terdapat pada bawang putih. Penelitian ini bertujuan untuk mengetahui pengaruh ekstrak bawang putih sebagai antioksidan terhadap gambaran histopatologi hati mencit BALB/c yang dipapar nikotin. Penelitian ini merupakan penelitian eksperimen dengan rancangan post-test only control group design. Subjek penelitian adalah mencit BALB/c jantan sebanyak 24 ekor. Kelompok K- adalah kontrol yang sehat. Kelompok K+ terpapar nikotin inhalasi 10 mg/kgBB. Kelompok P1 dan P2 diberi nikotin inhalasi 10 mg/kgBB dan diberi ekstrak bawang putih 300 mg/kgBB dan 500 mg/kgBB. Perlakuan diberikan selama 14 hari. Data dianalisis dengan uji Kruskal-Wallis dan dianggap signifikan jika p value < 0,05 dengan selang kepercayaan 95%. Degenerasi hati dikelompokkan menjadi normal, degenerasi parenkim, degenerasi hidropik, dan nekrosis. Hasil pada kelompok berikut: K: 80%, 20%, 0%, 0%; K(-): 0%,0%,87%,13%; P1 : 0%,60%,40%,0%; P2 : 0%,100%,0%,0%. Terdapat perbedaan derajat degenerasi yang bermakna antar kelompok ($p < 0,001$). Ekstrak bawang putih dapat mengurangi tingkat kerusakan mikroskopis pada hati mencit BALB/c yang terpapar nikotin secara inhalasi.

Kata kunci: garlic, liver, nikotin, histopatologi

How to cite:

Karoline W.M., Armalina D., Susilaningsih N., Istiadi H., Akhmad Ismail A. (2022). Effect of garlic extract on liver histopathology of BALB/c mice with nicotine exposure. *Indonesian Journal of Mathematics and Natural Science*, 45(2), 45-50.

INTRODUCTION

Nicotine is one of the important substances in cigarettes, both conventional cigarettes and e-cigarettes, which gives a pleasant taste so that smokers are addicted. Due to the many health issues caused by conventional cigarettes, conventional cigarette users switch to electronic cigarettes which are considered safer. People think that switching to e-cigarettes can reduce the health risks that arise (Caponnetto *et al.*, 2013). From the results of previous studies, it is known that e-cigarette smoke only leaves traces of nicotine (Czogala *et al.*, 2014). This is certainly one of the advantages of e-cigarettes compared to conventional cigarettes.

Besides being believed to be safer than conventional cigarettes, e-cigarettes come with a more modern and stylish appearance. This certainly attracts attention so that e-cigarette users increase (Damayanti., 2016). In Indonesia, the prevalence of electronic smokers also continues to increase. Based on Global Adult Tobacco Survey in 2011, the prevalence of electronic smokers aged 10-18 years in Indonesia is 0.3%. Based on National Health Indicator Survey (Survei Indikator Kesehatan Nasional) in 2016, the prevalence of electronic smokers aged 10-18 years in Indonesia rose to 2%, and based on the 2018 Riskesdas it rose to 2.7% (Badan Penelitian dan Pengembangan Kesehatan Kementerian RI tahun 2018, 2018; Badan Penelitian Pengembangan Kesehatan Kementerian Kesehatan RI, 2016; World Health Organization. Regional Office for South-East Asia, 2012). This increase in the prevalence of e-cigarettes certainly increases nicotine exposure for both users and others as passive smokers.

In e-cigarettes, nicotine is in liquid form and the nicotine product is in the form of a gas that the user will inhale. In 2014, the results of a study conducted by Callahan-Lyon *et al.* (2014) stated that there were variations in nicotine levels from 14.8 to 87.2 mg/ml in e-cigarette solutions (Callahan-Lyon, 2014). The existence of variations in nicotine levels in electronic cigarettes certainly needs to be a concern because too much nicotine will certainly affect the body. Nicotine will be metabolized by the cytochrome P450 (CYP) 2A6 enzyme in the liver to prevent the accumulation of these substances in the body (Delijewski *et al.*, 2019). In addition, nicotine isolate was shown in vitro to reduce NO availability due to oxidative stress (Chen *et al.*, 2019).

Based on previous research, it is known that exposure to e-cigarettes increases reactive oxygen species (ROS) (Shields *et al.*, 2017). The presence of these free radicals can cause oxidative stress so that cell and tissue damage can occur. This situation can be a factor in the occurrence of systemic disease or damage to vital organs, including the liver. Based on previous research, one of the consequences of nicotine exposure to the liver is fibrosis (Alexander *et al.*, 2018). Nicotine exposure to white rats at a dose of 1.5 mg/200g caused impaired liver function (Syahida, 2019). The liver plays an important role in metabolizing nicotine found in cigarettes so to protect liver function remains optimal due to free radical attack, the body needs antioxidants.

Antioxidants play an important role in neutralizing free radicals. One of the herbs that is easily found and believed to be an antioxidant is garlic. Garlic is widely used in cooking and the price is very affordable for all people, so the use of garlic extract as an antioxidant is one thing that can be applied in everyday life. Garlic contains many secondary metabolites that can be utilized. Allicin is the most abundant organosulfur in garlic which will provide a distinctive taste and aroma. This compound will appear when the garlic is cut or crushed. Allicin also plays a role in its antibacterial, antifungal, antioxidant, and anticancer (Gebreyohannes & Gebreyohannes, 2013). These antioxidants play a role in preventing cell damage due to oxidation of ROS that are formed due to nicotine exposure. Previous studies have stated that a dose of 300 mg/kgBW can cause an effect in experimental mice as an aphrodisiac (Maulita *et al.*, 2013). Another study stated that 500 mg/kgBW was able to cause anticancer effects in mice (Daniela, 2020). Based on these previous studies, the doses of 300 mg/kgBW and 500mg/kgBW was chosen because have been proven to be safe for mice.

Based on this background, conducting research on the effect of garlic extract as an antioxidant on the liver histopathological features of BALB/c mice exposed to nicotine is interesting.

METHODS

This study is an experimental study with a post-test only control group design. In this study, 24 male BALB/c mice with a body weight of 25-30 grams, aged 6-8 weeks, active and without defects were divided into four groups, each group consisting of 6 mice which were determined randomly. One hundred and ninety-three grams of garlic powder was extracted with 70% ethanol solvent for 3 x 24 hours while stirring. The extracted liquid is filtered so that the filtrate obtained can be collected and used using a cabinet dryer to obtain a thick extract. The healthy control group (K) is the group without

treatment. The negative control group (K-) was the group that was only exposed to inhaled nicotine of 10 mg/kgBW. The P1 group was the group that was exposed to inhaled nicotine 10 mg/kgBW and was given garlic extract at a dose of 300 mg/kgBW. The P2 group was the group that was exposed to 10 mg/kgBW inhaled nicotine and was given garlic extract at a dose of 500 mg/kgBW. P1 dan P2 group were given garlic extract in the morning and 30 minutes later given inhaled nicotine. The treatment was given for 14 days according to the group division after adaptation for 7 days.

Histopathological Examination of the Liver

After given treatment for 14 days, all mice were terminated by dislocating the cervical and their livers were taken to make histopathological preparations with HE staining. The preparations were read in five fields of view with a magnification of 400x. Based on that, each group had thirty observed fields of view. The assessment of the histopathological features of the liver was carried out based on the Manja Roenigk Histopathology Scoring system (Widigdo,2014).

Table 1. Manja Roenigk histopathology scoring system

Cell type	Score
Normal	1
Parenchymal degeneration	2
Hydrophic degeneration	3
Necrosis	4

Data Analysis

Data were analyzed by Kruskal-Wallis non-parametric test followed by Mann-Whitney test. The difference was considered significant if the p value <0.05 with 95% confidence interval.

Ethical Clearance

The research has requested ethical clearance from the Health Research Ethics Commission (KEPK) of the Faculty of Medicine, Diponegoro University with ethical clearance number 52/EC/H/FK-UNDIP/V/2021

RESULTS AND DISCUSSION

During the study, there were no samples that dropped out. Data on the percentage of liver damage for each group can be seen in Table 2. Histopathological description of the liver of BALB/c mice at 400x magnification is presented in the following figures 1.

The results of the normality test of the percentage of liver damage distribution using the Saphiro-Wilk test showed that the data was not normally distributed with a significance value of less than 0.05. Furthermore, the hypothesis was tested using the Kruskal Wallis test and found a significant difference in the degree of degeneration between groups with a significance value of less than 0.05, namely <0.001. The test was continued with Mann-Whitney to assess whether there was a difference between the two groups. Based on the Mann-Whitney test, the results showed that there were significant differences between groups K and K (-) (<0.001), K and P1 (<0.001), K and P2 (<0.001), K(-) with P1 (<0.001), K(-) with P2 (<0.001), and P1 to P2 (<0.001).

Tabel 2. Percentage of liver damage for each group (30 fields of view for each group)

Group	Cell Type			
	Normal	Parenchymal degeneration	Hydrophic degeneration	Necrosis
K	24 (80%)	6 (20%)	0 (0%)	0 (0%)
K -	0 (0%)	0 (0%)	26 (86.66%)	4 (13.33%)
P 1	0 (0%)	18 (60%)	12 (40%)	0 (0%)
P 2	0 (0%)	30 (100%)	0 (0%)	0 (0%)

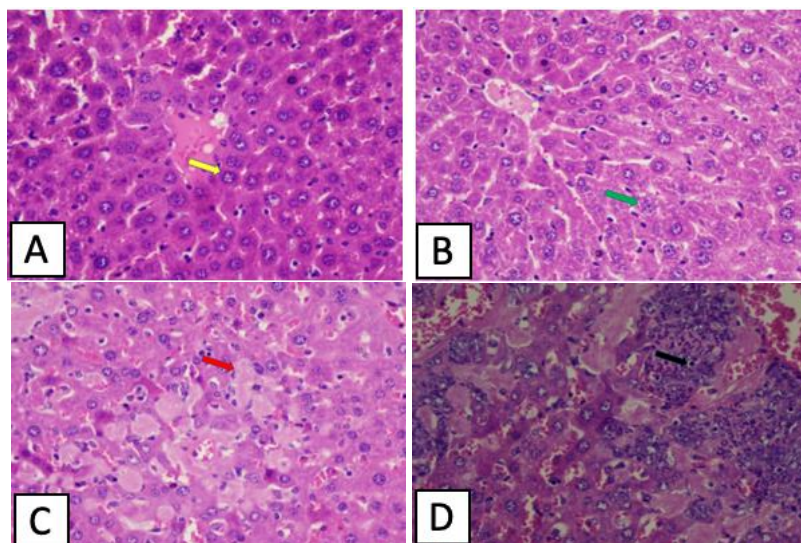


Figure 1. Histopathology features using 400x magnification of normal hepatocytes (A), parenchymal degeneration of hepatocyte (B), hydropic degeneration of hepatocyte (C), necrosis of hepatocyte (D). At 400x magnification, normal liver cells (yellow arrow) are polygonal in shape with homogeneous red cytoplasm and well-defined cell walls. Parenchymal degeneration hepatocytes are accompanied by cloudy and granular cytoplasm (green arrow). The liver cells that are hydropic degenerated (red arrow) are swollen have vacuoles. Necrotic liver cells were seen (black arrow) where the cells appeared to have nuclear changes, lost chromatin, and were dark in color. In this field of view it can also be seen that the liver cells are replaced by inflammatory cells.

Tabel 3. Mann-Whitney test

Group	K	K-	P1	P 2
K	-			
K-	<0.001*	-		
P1	<0.001*	<0.001*	-	
P2	<0.001*	<0.001*	<0.001*	-

*: significant

The results showed that garlic extract had the potential as a hepatoprotector in BALB/C mice exposed to inhaled nicotine. The liver is the center of metabolic disposition of foreign materials that enter the body. One of the foreign substances that can affect the liver is nicotine. Nicotine will increase ROS and cause oxidative stress. Most of the nicotine is metabolized by the liver where there is a role for cytochrome P-450 2A6 (CYP2A6) to catalyze nicotine (Widigdo, 2014). CYP2A6 protein is mostly found in the liver where this protein is different from other liver CYP proteins because CYP2A6 protein only plays a role in the metabolism of some drugs. The two most relevant substrates for CYP2A6 are coumarin and nicotine where 80% of the nicotine dose is eliminated by this protein (Lingga, 2014). The administration of garlic extract containing allicin as organosulfur components that acts as an antioxidant protecting the liver from the effects of free radicals due to nicotine exposure (Untari, 2010).

The healthy control group was the group that was only given standard feed without any administration of garlic extract or nicotine. In observations with 400x magnification for the negative control group (K), it was found that most of the hepatocytes were still in normal condition, namely 80% of the 30 observation fields. Meanwhile, in 20% of the other visual fields, minor damage was found which was parenchymatous degeneration. It was found that there was minor damage to the six visual fields observed where this damage could occur due to stress factors or liver cells that had been damaged prior to the study. The occurrence of liver damage in mice in the healthy control group was probably due to the use of mice that were not Specific Pathogen Free (SPF) mice. This is in accordance

with previous research that the healthy control group mice also suffered liver damage (Prasetyo *et al.*, 2019).

Based on observations using 400x magnification for the negative control group (K-), it was found that most hepatocytes experienced hydropic degeneration in 87% of the 30 visual fields observed. Meanwhile, in 13% of the other visual fields, necrosis was found. This happened because the K(-) group was not given antioxidants, resulting in an imbalance between oxidants and antioxidants. This severe damage is caused by the presence of exogenous free radicals, namely cigarette smoke and endogenous free radicals due to the metabolism of nicotine (Shang *et al.*, 2019). These free radicals will trigger the formation of lipid peroxidation and affect DNA and membrane proteins resulting in cell damage (Shang *et al.*, 2019). This is in accordance with previous research that exposure to inhaled nicotine can have an effect on the liver (Alexander *et al.*, 2018; Syahida, 2019).

Microscopic observation of the first treatment group (P1) showed that most of the hepatocytes experienced parenchymatous degeneration in 60% of the 30 visual fields observed. Meanwhile, in the other 40% of the field of view hydropic degeneration was found. In this first treatment group, no necrosis was found. In the P1 group, mild to severe damage was found. Garlic which acts as a hepatoprotector will affect the production of glutathione which protects cells from free radicals. Previous research has also stated that garlic can improve the stability of hepatocyte cell membranes (Kumar *et al.*, 2013). The difference in the degree of degeneration in the P1 group can be influenced by genetic factors so that there are differences in nicotine metabolism (Raunio & Rahnasto-Rilla, 2012).

The results of microscopic observation of the liver using 400x magnification in the second treatment group (P2), found moderate damage which was parenchymatous degeneration in the entire observed field of view. In this second treatment group, no moderate-severe damage was found, namely hydropic degeneration and necrosis. This shows that garlic extract at a dose of 500 mg/kgBW is able to prevent severe damage due to nicotine exposure but unable to maintain normal cells. Garlic extract at a dose of 500 mg/kgBW is the optimal dose in this study. This is in accordance with previous studies which showed that garlic extract was able to accelerate the regeneration of hepatocytes so that no further damage occurred (Harsa, 2020).

CONCLUSION

There are differences in the microscopic appearance of the liver of BALB/c mice in the treatment group exposed to nicotine and given garlic extract (*Allium sativum*) at a dose of 300 mg/kgBW and 500 mg/kgBW with the control group. Also, there are differences in the microscopic appearance of the liver of BALB/C mice between treatment groups with different doses.

ACKNOWLEDGEMENTS

This work was supported by Department of Anatomy and Histology, Faculty of Medicine, Diponegoro University. This research funding is sourced from the first author's parents.

CONFLICT OF INTEREST

The authors declare no competing interests.

REFERENCES

- Alexander, C. E. L., Drummond, C. A., Hepokoski, M., Mathew, D., Moshensky, A., Willeford, A., Das, S., Singh, P., Yong, Z., Lee, J. H., Vega, K., Du, A., Shin, J., Javier, C., Tian, J., Brown, J. H., & Breen, E. C. (2018). Chronic inhalation of e-cigarette vapor containing nicotine disrupts airway barrier function and induces systemic inflammation and multiorgan fibrosis in mice. *American Journal of Physiology - Regulatory Integrative and Comparative Physiology*, 314(6), R834–R847. <https://doi.org/10.1152/ajpregu.00270.2017>
- Badan Penelitian dan Pengembangan Kesehatan Kementerian RI tahun 2018. (2018). *Laporan hasil riset kesehatan dasar (Riskesdas) Indonesia 2018*. http://labdata.litbang.kemkes.go.id/images/download/laporan/RKD/2018/Laporan_Nasional_RKD2018_FINAL.pdf
- Badan Penelitian Pengembangan Kesehatan Kementerian Kesehatan RI. (2016). *Survei Indikator Kesehatan Nasional*. <https://labmandat.litbang.kemkes.go.id/riset-badan-litbangkes/menu-riskesnas/menu-rikus/422-sirk-2016>
- Callahan-Lyon, P. (2014). Electronic cigarettes: Human health effects. *Tobacco Control*, 23(SUPPL. 2).

- <https://doi.org/10.1136/tobaccocontrol-2013-051470>
- Caponnetto, P., Campagna, D., Cibella, F., Morjaria, J. B., Caruso, M., Russo, C., & Polosa, R. (2013). Efficiency and Safety of an eElectronic cigAreTte (ECLAT) as Tobacco Cigarettes Substitute: A Prospective 12-Month Randomized Control Design Study. *PLoS ONE*, 8(6), 1–12. <https://doi.org/10.1371/journal.pone.0066317>
- Chen, X., Wang, K., Cederbaum, A. I., & Lu, Y. (2019). Suppressed hepatocyte proliferation via a ROS-HNE-P21 pathway is associated with nicotine- and cotinine-enhanced alcoholic fatty liver in mice. *Biochemical and Biophysical Research Communications*, 512(1), 119–124. <https://doi.org/10.1016/j.bbrc.2019.03.021>
- Czogala, J., Goniewicz, M. L., Fidelus, B., Zielinska-Danch, W., Travers, M. J., & Sobczak, A. (2014). Secondhand exposure to vapors from electronic cigarettes. *Nicotine and Tobacco Research*, 16(6), 655–662. <https://doi.org/10.1093/ntr/ntt203>
- Damayanti A. (2016). Penggunaan Rokok Elektronik di Komunitas Personal Vaporizer Surabaya. *J FKM Univ Airlangga*. <https://doi.org/10.20473/jbe.v4i2.2016.250>
- Daniela C, B. D. (2020). Efektivitas Senyawa Sulfida Pada Bawang Putih Terhadap Resiko Kanker Paru-Paru. *XVII(2)*, 170–177.
- Delijewski M, Bartoń A, Delijewska P, Balwierz R, Jakubiak G, Kośmider L, P. N. (2019). Genetically determined metabolism of nicotine and its clinical significance. *Acta Biochim Pol*.
- Gebreyohannes, G., & Gebreyohannes, M. (2013). Medicinal values of garlic: A review. *International Journal*, 5(9), 401–408. <https://doi.org/10.5897/IJMMS2013.0960>
- Harsa, M. S. (2020). Efek pemberian ekstrak etanol bawang putih (*Allium sativum*) sebagai hepatoprotektor pada tikus putih jantan galur wistar (*Rattus norvegicus*) yang diinduksi parasetamol dosis hepatotoksik. *Intisari Sains Medis*, 11(1), 118. <https://doi.org/10.15562/ism.v11i1.666>
- Kumar, S., Kumar, A., & Chandra, A. (2013). Alteration in serum biochemical parameters due to garlic (*Allium sativum*) supplementation in broilers diets. *African Journal of Biotechnology*, 12(29), 4691–4698. <https://doi.org/10.5897/ajb12.2724>
- Lingga, L. (2014). *Terapi Bawang Putih untuk Kesehatan*. Elex Media Komputindo.
- Maulita, I., Rahimah, S., Umar, A. H., & Allyah, A. P. (2013). Uji Efek Afrosidiaka dari Ekstrak Bawang Putih (*Allium sativum*) pada Hewan Coba Mencit (*Mus musculus*). *Akademi Farmasi Kebangsaan*, 2, 140–144.
- Prasetyo, Y. E., Merdana, I. M., Kardena, I. M., & Sudira, I. W. (2019). Gambaran Histopatologi Hepar Mencit Yang Diberikan Ekstrak Etanol Sarang Semut. *Buletin Veteriner Udayana*, 21, 44. <https://doi.org/10.24843/bulvet.2019.v11i1.p08>
- Raunio, H., & Rahnasto-Rilla, M. (2012). CYP2A6: Genetics, structure, regulation, and function. *Drug Metabolism and Drug Interactions*, 27(2), 73–88. <https://doi.org/10.1515/dmdi-2012-0001>
- Shang, A., Cao, S. Y., Xu, X. Y., Gan, R. Y., Tang, G. Y., Corke, H., Mavumengwana, V., & Li, H. Bin. (2019). Bioactive compounds and biological functions of garlic (*allium sativum* L.). *Foods*, 8(7), 1–31. <https://doi.org/10.3390/foods8070246>
- Shields, P. G., Berman, M., Brasky, T. M., Freudenheim, J. L., Mathe, E., McElroy, J. P., Song, M. A., & Wewers, M. D. (2017). A review of pulmonary toxicity of electronic cigarettes in the context of smoking: A focus on inflammation. *Cancer Epidemiology Biomarkers and Prevention*, 26(8), 1175–1191. <https://doi.org/10.1158/1055-9965.EPI-17-0358>
- Syahida, R. Y. (2019). *Pengaruh Pemberian Asap Rokok Elektrik Vapor Terhadap Kadar Sgpt Dan Sgot Hepar Pada Tikus Putih (Rattus Norvegicus)*. Sarjana thesis, Universitas Brawijaya.
- Untari, I. (2010). *Bawang Putih Sebagai Obat Paling Mujarab Bagi Kesehatan*. Surakarta: Muhammadiyah Surakarta. *Ilmu Keperawatan*, 7.
- Widigdo, A. P. (2014). *Pengaruh Pemberian Dosis Bertingkat Madu Terhadap Gambaran Mikroskopis Hepar Pada Mencit Strain Balb/C Jantan Yang Diberi Paparan Asap Rokok*.
- World Health Organization. Regional Office for South-East Asia. (2012). *Global adult tobacco survey: Indonesia report 2011*. <https://apps.who.int/iris/handle/10665/205137>