

# Intestinal Protective Efficacy of Gamma Co-60 Irradiated Chitosan and Vitamin E Combination on Lead acetate-induced Rats

Aditya Marianti , Edward Louis Krey, Wulan Christijanti, Lisdiana

Department of Biology, Faculty of Mathematics and Natural Science, Universitas Negeri Semarang, Indonesia

\*Corresponding Author: [aditya.marianti.am@mail.unnes.ac.id](mailto:aditya.marianti.am@mail.unnes.ac.id)

Submitted: 2022-01-31. Revised: 2022-02-13. Accepted: 2022-03-30.

**Abstract.** As an organ that absorbs food, the intestine can be damaged when interacting directly with lead (Pb). Gamma Co-60 irradiated chitosan, and vitamin E combination potentially can help reduce free radical damage to intestinal organs. This study examines the efficacy of gamma Co-60 irradiated chitosan and vitamin E combination in protecting the intestinal tissue of rats exposed to Pb acetate. The 24 rats were grouped into 6 groups, each 4 rats; were induced with Pb acetate, except the control group. The negative control group was only induced Pb acetate. The positive control group had additional treatment of irradiated chitosan. The treatment group (1-3) was treated using the combination of gamma Co-60 irradiated chitosan at a dose of 64 mg/kg BW and vitamin E 1000 IU at a dose of 1.44; 2.16, 3.00 mg/kg BW, respectively, for forty days. The research parameters observed are edema, degeneration, necrosis, erosion of the intestinal villi, and lysis of the intestinal villi. Intestinal histology appearance data in all groups were analyzed descriptively. The result shows that a combination of Gamma Co-60 irradiated chitosan at a dose of 64 mg/kg BW and vitamin E at a dose of 1.44 mg/kg BW effectively reduced lead cytotoxicity in the intestinal tissue of Pb acetate-induced rats. The larger the dose of vitamin E has the potential to produce pro-oxidants, which will increase the toxic effect on intestinal tissue. Gamma Co-60 irradiated chitosan, and vitamin E combination at the right dose has the potential to be developed as a supplement to reduce the toxic effects of chronic lead exposure. Especially for people who, for some reason, cannot avoid chronic lead exposure.

**Key words:** Chitosan, Gamma Co-60, lead intoxication, vitamin E

**How to Cite:** Marianti, A., Krey, E. L., Christijanti, W., & Lisdiana, L. (2022). Intestinal Protective Efficacy of Gamma Co-60 Irradiated Chitosan and Vitamin E Combination on Lead acetate-induced Rats. *Biosaintifika: Journal of Biology & Biology Education*, 14 (1), 75-81.

**DOI:** <https://doi.org/10.15294/biosaintifika.v14i1.34822>

## INTRODUCTION

World Health Organization (WHO) in 2021 reported that chronic Pb poisoning caused more than two million deaths worldwide, with the highest mortality in developing countries such as Indonesia. Lead in the human body can come from various sources such as the metal processing industry, the pesticide industry, the mining industry, the metal coating industry, and paint stripping (Istarani & Pandebesie, 2014). In addition, lead is also widely used in everyday life, such as pesticides in vegetables through lead-contaminated soil from pesticides (Frank et al., 2019). Lead as heavy metal is hazardous to human health. Lead can accumulate in the body and cause acute and chronic poisoning (Ray, 2016).

Lead poisoning through the oral route can occur mainly from eating or drinking water contaminated with lead. Some traditional medicines (ayurvedic medicines example), contain heavy metals, including lead. Lead toxicity can also be caused by consuming lead-contaminated fruits and vegetables from the soil

where they are grown (Wani et al., 2015). Lead that enters the body causes detrimental effects on the intestine. Harahap (2017) reported microscopic changes in epithelial necrosis and shortening of the jejunal villi of mice exposed to lead orally, which also happened edema in the intestinal mucosa.

Lead acetate exposure impacts the lipid peroxidation process. Lipid peroxidation occurs because Pb compounds that enter the body will become Pb<sup>2+</sup> ions which can bind to the sulfhydryl group owned by the body's antioxidant enzymes, which causes the enzyme's ability to decrease, thereby increasing the amount of ROS. The most reactive group of ROS is the hydroxyl radicals (-OH) group, which react with PUFAs in cell membranes; this reaction is called lipid peroxidation (Ghassana et al., 2020). Lead produces ROS, disrupting essential body elements, damaging or destroying cell membranes, and inhibiting antioxidant enzymes, especially those with sulfhydryl groups (Omid et

al., 2020). Exposure to lead affects the histological structure of the intestine. Several damages can characterize edema, fat degeneration, necrosis, erosion of the intestinal villi, and lysis of the intestinal villi (Ismaya et al., 2017).

Vitamin E (alpha tocopherol) is a fat-soluble vitamin, and a potent antioxidant believed to be important in protecting cells from oxidative stress. Vitamin E plays a vital role in protecting cell membranes rich in highly unsaturated fatty acids from oxidative damage (Raederstorff et al., 2015). The combination of antioxidant ingredients can reduce damage to cells. The use of chitosan as an antioxidant additive has been reported in many studies, showing its ability to interact with free radicals through ionic interactions with amino groups (Mahdy et al., 2013). Chitosan can scavenge free radicals or metal ions from hydrogen reactions or lone pairs of electrons. The fact that chitosan exhibits intense metal ion chelating ability suggests that it could be a potential natural product (Rajalakshmi et al., 2013).

Chitosan in chelating Pb ions based on Marianti & Mahatmanti's (2018) research has not been very effective; this is presumably because chitosan has a large particle size, so it is challenging to enter cell tissue. Therefore, efforts need to be made to reduce the size by irradiating chitosan. The results of chitosan radiation with gamma Co-60 showed a significant increase in solubility and antioxidant activity due to water solubility and high efficiency of antioxidant activity. Thus chitosan has the potential to be used for various purposes, especially as an antioxidant (Son et al., 2017). This study examines the efficacy of gamma Co-60 Irradiated Chitosan and vitamin E combination in protecting the intestinal tissue of rats exposed to Pb acetate.

## METHOD

### Animal housing

This study used 24 male white rats of the Wistar strain obtained from Laboratorium Penelitian dan Pengujian Terpadu (Integrated Research and Testing Laboratory) Unit 4 Universitas Gadjah Mada Indonesia. The rats were healthy, with bodyweight ranging from  $200 \pm 10$  g. Furthermore, the mice were reared in the Laboratory of Animal Physiology of Biology Department Faculty Mathematics and Natural Sciences Universitas Negeri Semarang, Indonesia. Rats were given standard feed and drink ad libitum. The ethical clearance was issued by The

Medical/Health Research Bioethics Commission, Faculty of Medicine Universitas Islam Sultan Agung Semarang, Indonesia with approval number of 665/X/2019/Komisi Bioetik.

### Chitosan Irradiated Gamma Co-60

Chitosan comes from crustacean shells with Mesh size 100-300 powder and deacetylation degree minimal 94% (produced by CV Chi Multiguna), was irradiated with Gamma Cobalt-60 at a dose of 150 kGy from Gamma Chamber 400 A. The irradiation was carried out at the Isotope and Radiation Application Center (PAIR) of the National Atomic Energy Agency (BATAN), Jakarta, Indonesia.

### Vitamin E

Vitamin E used is DL Alpha Tocopherol Acetate 1000 IU (produced by Zhejiang Medicine Co. LTD)

### Experimental Procedure

Twenty-four male rats were randomly assigned to 4 treatment groups, each group was given the following treatment : The control group (KK), the negative control group (K-) was given Pb acetate 175 mg/kg Body Weight (BW), the positive group (K+) was given Pb acetate (175 mg/kg BW) + irradiated chitosan (64 mg/kg BW), the treatment group 1 (KP 1) was given Pb acetate (175 mg/kg BW) + irradiated chitosan (64 mg/Kg BW rats) + Vitamin E (1.44 mg/kg/BW rats), the treatment group 2 (KP 2) was given Pb acetate (175 mg/kg BW) + Chitosan (64 mg/Kg BW) + Vitamin E (2.16 mg/kg/BW), the treatment group 3 (KP 3) was given Pb acetate (175 mg/kg BW) + Chitosan (64 mg/kg BW) + Vitamin E (3.00 mg/kg/BW rats). The treatment in each group was given for 40 days on the day 41<sup>st</sup> the rats were terminated after being first anesthetized with chloroform and decapitated,

### Isolation and fixation of intestinal organ

After dissection, the Intestinal organ was taken and washed with physiological saline solution (0.95% NaCl), followed by fixation using 4% paraformaldehyde (PFA) solution. The organ samples were prepared for histology using the paraffin method and Hematoxylin-Eosin (HE) staining at the Anatomical Pathology Laboratory, Faculty of Veterinary Medicine, Universitas Gadjah Mada Indonesia.

### Paraffin method

The intestinal tissue is dehydrated in an ethanol

sequence, cleaned with xylene, and embedded in paraffin (Adams, 2013; Sadeghipour and Babaheidarian, 2019). After the paraffin hardens, it is cut with a microtome with a size of 5-10 micrometers. Then the staining is carried out using the Hematoxylin-Eosin (HE) method. The next step is mounting, which is closing the preparation with a cover glass. The slides were stained with HE, covered with Canadian balsam, and labeled. The following process analyzes preparations using a light microscope with a magnification of between 100 and 400 times.

### Data analysis

Each slide of intestinal histology samples was observed under a microscope in 5 different fields of view with a magnification of 400 times each. The data were analyzed descriptively to find out the difference in the effect of the small intestine histology in each sample group.

## RESULTS AND DISCUSSION

The histological observations were analyzed based on edema, degeneration, necrosis, erosion of the intestinal villi, and lysis of the intestinal villi. Table 1. Table of the level of cell damage in each treatment.

villi, which were evenly distributed in most intestinal cell tissues. Pb as a heavy metal that enters the body can cause damage to the intestines, only edema in the intestinal mucosa.

Compared with the negative control group, the positive control group given Pb acetate with chitosan showed minor damage to organs such as necrosis than the negative control group; this indicates that chitosan can chelate and protect tissues from rat organs exposed to lead. Acetate, these results follow research conducted by Marianti *et al.*, (2017). Treatment group 1, based on table 1, shows that the level of damage is slightly higher than the positive control group, which is shown in the data for each field of view that more damage occurs. Treatment group 2 shows an increase in damage and the increase in the dose of vitamin E; although normal cells were still found with the same number, the type of damage was more severe, namely increased erosion of the villi. Treatment group 3, when compared to treatments 1 and 2, showed an increase in the level of tissue damage to the villi so that many villi were necrotic. Treatments 1, 2, 3, with increasing doses of vitamin E given to rats, showed increased damage to intestinal cells, especially in the number of erosions of the villi.

Chronic exposure to Pb<sup>2+</sup> ions triggers damage

**Table 1.** The level of cell damage in each treatment

Group	Intestinal Damage (%)					
	No	Ed	De	Ne	Er	Li
KN	87	13	0	0	0	0
K-	0	7	20	33	33	7
K+	40	20	13	13	13	0
KP1	27	13	27	13	20	0
KP2	27	20	7	13	33	0
KP3	13	13	20	20	33	0

Description: No = Normal, Ed = Edema, De = Degeneration, Ne = Necrosis, Er = Erosion of vili, Li = Lysis of villi

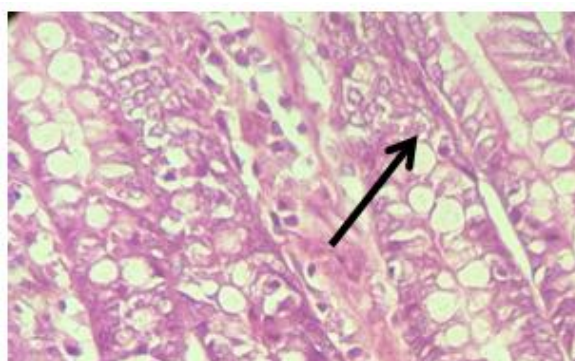
In the observation of the control group, the negative control group, the positive control group, treatment group 1, treatment group 2, and treatment group 3 give different results. In general, the intestine can be divided into three parts or layers, namely the mucosa, submuscularis, and muscularis externa; the mucosa is the outermost layer of the histology of the rat intestine. Histopathological results from the ileum of rats in the control group showed normal-looking mucosal cells. On the other hand, the negative control group showed significant changes, marked by damage to the intestines of rats in the form of edema, bleeding, necrosis, and even erosion of the

to intestinal tissue, which stimulates oxidative stress. The mechanism of oxidative stress by Pb is initiated by increasing ROS (Reactive Oxygen Species) (Aprilia, 2015). Normally, the concentration of ROS is maintained by antioxidant enzymes and the synthesis of antioxidant compounds because the presence of ROS is needed in the body in a balanced condition, but if the production and detoxification of ROS are imbalanced, oxidative stress can occur. (Szymanski & Lewis, 2015). This reaction occurs because Pb that enters the body will interfere with

One of the enzymes that function as a defense when oxidative stress occurs, namely glutathione (GSH). GSH is one of the endogenous antioxidants enzymes necessary in defense against ROS. Lead in the body can interfere with the function of GSH by forming a complex with lead (Fan et al., 2010) so that GSH cannot function optimally and causes an increase in ROS. Increased ROS causes tissue damage, inflammatory processes, and cell apoptosis. In the end, this oxidative stress will cause dysfunction in intestinal cells.

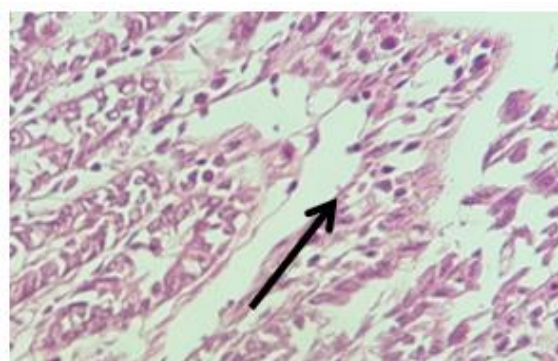
The percentage of intestinal tissue damage due to Pb exposure in the positive control group or the group given chitosan was lower than in the negative control group (table 1). This percentage is because the free radical damage of Pb<sup>2+</sup> ions is reduced by the chelation of chitosan on Pb<sup>2+</sup> ions. Chitosan can chelate Pb<sup>2+</sup> ion through the amine group on chitosan, which can be seen in Figure 7:

The presence of nitrogen electrons in the amino group will form bonds with transition heavy metal ions, and then chitosan will form chelates with heavy metal ions by releasing hydrogen ions. (Fan



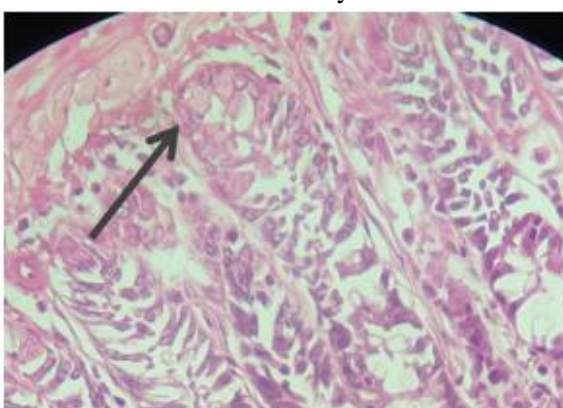
**Figure 1.** Intestinal histopathological description of the treatment group 1. With 400X magnification. Normal cells (arrow)

Description: Normal cells are characterized by the intensity of color in cells that are more homogeneous than abnormal cells; in other words, normal cells have a smoother texture than the texture of abnormal cells, and the presence of these cells can be seen clearly



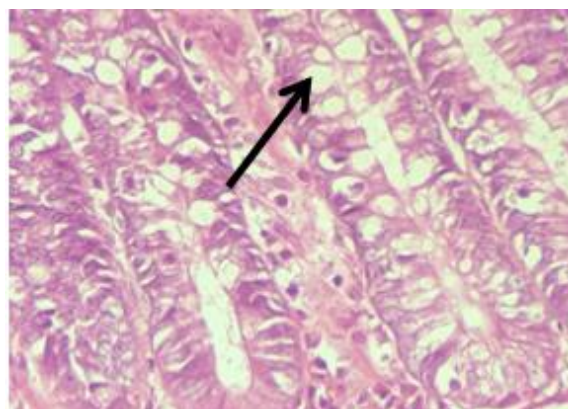
**Figure 2.** Intestinal histopathology of the positive control group. With 400X magnification. Edema cells (arrow)

Description: Edema in the intestine is an extraordinary increase in vascular permeability due to increased fluid in the intracellular compartment



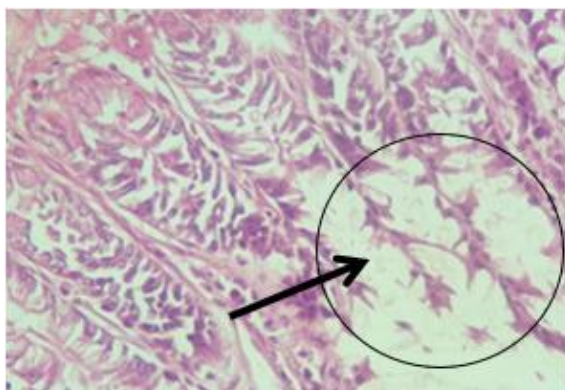
**Figure 3.** Histopathological picture of the treatment group 2. With 400X magnification. Cells degenerate (arrow).

Description: Cell degeneration or cell decline is a cell abnormality that occurs due to minor injury to structures in cells such as mitochondria and cytoplasm that will interfere with cell metabolic processes

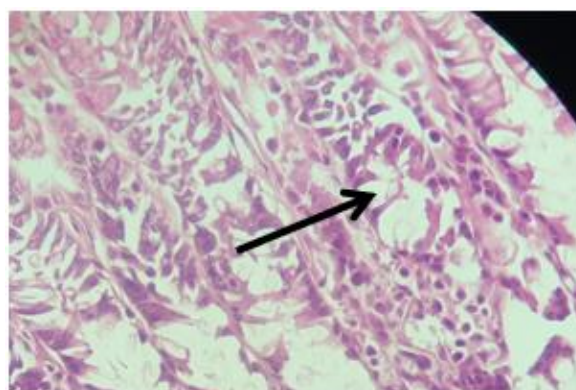


**Figure 4.** Intestinal histopathological Description of the treatment group 1. With 400X magnification. Cells undergo necrosis (arrow). Description: necrosis of the intestine is a stage of the disease process characterized by cell death due to reduced blood flow to the digestive tract, which can be seen from the absence of cell nuclei.

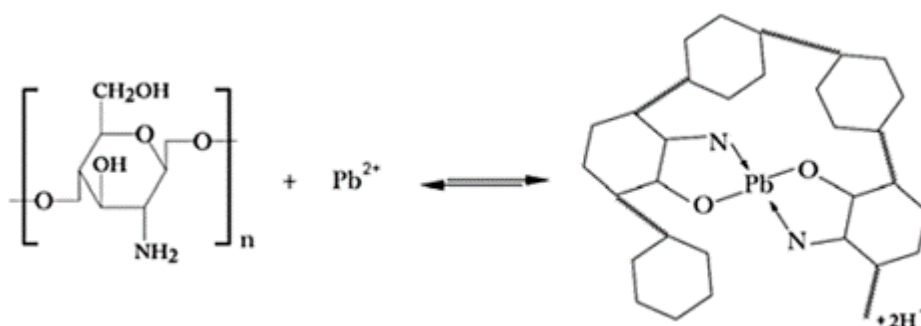




**Figure 5.** Intestinal histopathological description of the treatment group 2. With 400X magnification. Erosion of villi ( arrow and circle). Description: Erosion of the villi is a condition of intestinal cells that have lost some of the epithelium in the mucosal layer of the small intestine so that the thickness of the small intestine mucosa becomes lower



**Figure 6.** Histopathological picture of the treatment group 2. With 400X magnification. Cell lysis (arrow). Description: lysis is tissue damage when the cell breaks and the cell nucleus disappears; this stage will be followed by necrosis, namely cell death.



**Figure 7.** Formation of  $Pb^{2+}$  chelation by chitosan

et al., 2010). The chelation of  $Pb^{2+}$  ions by chitosan causes  $Pb^{2+}$  ions to be stable, and ROS levels in the body will not increase so that oxidative stress can be minimized.

In treatment groups 1, 2, and 3, based on the data in table 1, there is a tendency to increase intestinal tissue damage and the increase in the dose of vitamin E given. Treatment group 3, the group with the highest dose of vitamin E, showed the least number of normal cells after the negative control group and an increase in damage parameters in the form of necrosis compared to treatment groups 1 and 2. According to Zachariah (2011), intestinal necrosis is the initial stage of the emergence of the disease, which is characterized by cell death due to reduced blood flow to the digestive tract.

Vitamin E is a potent chain-breaking antioxidant that inhibits the production of ROS molecules. A decrease in the percentage of normal cell numbers in the treatment group receiving high

doses of vitamin E may be possible because there is an imbalance between antioxidant levels and the body's needs. Excess antioxidants will cause these antioxidants to turn into pro-oxidants. This condition has been confirmed by research results from several researchers (Roziara et al., (2016); Koçyiğit & Selek, (2016), Omaye (2019)). Pro-oxidants are compounds that induce oxidative stress by generating ROS; these compounds can include all molecules containing reactive free radicals in cells or tissues, antioxidant groups such as ascorbic acid, vitamin E, polyphenols that react with heavy metals (Rahal et al., 2014). By such means, a precise vitamin E dose must be applied to obtain the most optimum benefit.

Chitosan has been known as a heavy metal adsorbent in aquatic and industrial environments. However, chitosan as a heavy metal chelator of Pb in the blood of people who are chronically exposed to Pb has not been developed. This study proves the potential of chitosan to overcome the



- Rahal, A., Kumar, A., Singh, V., Yadav, B., Tiwari, R., Chakraborty, S., & Dhama, K. (2014). Oxidative stress, pro-oxidants, and antioxidants: The interplay. *BioMed Research International*, 2014. <https://doi.org/10.1155/2014/761264>
- Rajalakshmi, A., Krithiga, N., & Jayachitra, A. (2013). Antioxidant activity of the chitosan extracted from shrimp exoskeleton. *Middle East Journal of Scientific Research*, 16(10), 1446–1451. <https://doi.org/10.5829/idosi.mej.sr.2013.16.10.12033>
- Rakhim, A., & Syamsianah, A. (2018). Hubungan Konsumsi Sumber Makanan Prooksidan Eksogen dengan Status Anemia Pada Ibu Hamil di wilayah Puskesmas Kaligangsa Kabupaten Brebes. *Repository Unimus*.
- Ray, R. R. (2016). Haemotoxic Effect of Lead: A Review. *Proceedings of the Zoological Society*, 69(2), 161–172. <https://doi.org/10.1007/s12595-015-0160-9>
- Roziana, R., Subagio, H. W., Suhartono, S., & Widyastiti, N. S. (2016). Pengaruh suplementasi vitamin e ( $\alpha$ -tokoferol) terhadap kadar gamma glutamil transferase (ggt) dan kadar nitric oxide (no) pada tikus (Studi pada tikus rattus novergicus strain wistar jantan terpapar inhalasi uap benzene). *Jurnal Gizi Indonesia (The Indonesian Journal of Nutrition)*, 3(2), 73–79. <https://doi.org/10.14710/jgi.3.2.73-79>
- Sadeghipour, A., and Babaheidarian, P. (2019). Making formalin-fixed, paraffin embedded blocks. *Methods Mol. Biol.* 1897, 253–268. doi: 10.1007/978-1-4939-8935-5\_22
- Son, B. H. D., Mai, V. Q., Du, D. X., Phong, N. H., Cuong, N. D., & Khieu, D. Q. (2017). Catalytic wet peroxide oxidation of phenol solution over Fe–Mn binary oxides diatomite composite. *Journal of Porous Materials*, 24(3), 601–611. <https://doi.org/10.1007/s10934-016-0296-7>
- Szymanski, D. M., & Lewis, J. A. (2015). Race-Related Stress and Racial Identity as Predictors of African American Activism. *Journal of Black Psychology*, 41(2), 170–191. <https://doi.org/10.1177/0095798414520707>
- Wani AL, Ara A, Usmani JA. (2015). Lead toxicity: a review. *Interdiscip Toxicol.* Vol 8(2):55- 64. doi: 10.1515/intox-2015-0009.
- World Health Organization. Exposure to Lead: A major public health concern. *World Heal Organ.* 2021;6.
- Zachariah, S. K. (2011). Adult necrotizing enterocolitis and non occlusive mesenteric ischemia. *Journal of Emergencies, Trauma, and Shock*, 4(3), 430. <https://doi.org/10.4103/0974-2700.83881>